

# CASE REPORT

---

## LYMPHEDEMA DISTICHIASIS SYNDROME – A RARE CASE REPORT

Dayanand S Biradar<sup>1</sup>, Hemanth kumar M<sup>2</sup>, Supreet Ballur<sup>3</sup>

### HOW TO CITE THIS ARTICLE:

Dayanand S Biradar, Hemanthkumar M, Supreet Ballur. "Lymphedema distichiasis syndrome – A Rare Case report". Journal of Evolution of Medical and Dental Sciences 2013; Vol2, Issue 34, August 26; Page: 6406-6410.

**ABSTRACT:** Lymphedema-distichiasis syndrome is a condition that affects the normal function of the lymphatic system (part of the immune system that produces and transports fluids and immune cells throughout the body). People with this condition develop puffiness or swelling (lymphedema) of the limbs, typically the legs and feet. Another characteristic of this syndrome is the growth of extra eyelashes (distichiasis), ranging from a few extra eyelashes to a full extra set on both the upper and lower lids. These eyelashes do not grow along the edge of the eyelid, but out of its inner lining. Related eye problems can include an irregular curvature of the cornea causing blurred vision (astigmatism) or scarring of the cornea. Other health problems associated with this disorder include swollen and knotted (varicose) veins, droopy eyelids (ptosis), heart abnormalities, and an opening in the roof of the mouth (a cleft palate). All people with lymphedema-distichiasis syndrome have extra eyelashes present at birth; however, the age of onset of lymphedema varies. Males usually develop lymphedema earlier than females, but all those affected will develop lymphedema by the time they are in their forties. We report here one such rare case which is one among few cases reported.

**KEY WORDS:** lymphedema distichiasis syndrome (LDS), Distichiasis, lymphedema (LE) MeSH terms- lymphedema distichiasis syndrome (LDS)

**INTRODUCTION:** Primary lymphatic disorder, or a disorder of lymphatic development which affects 1 in 10,000 individuals. Many found to have a genetic component, such as a mutation in the genes that are linked to lymphatic development. LE distichiasis syndrome (LDS) is one example of a primary lymphatic disorder with a known genetic component [1]. Rare, autosomal dominant disorder of pubertal onset, associated with distichiasis associated with FOXC2 gene mutations. [2]. Lymphedema can be congenital in onset.[8] Distichiasis (fig.2) is a congenital anomaly in which accessory eyelashes occur along the posterior border of the lid margins in the position of the Meibomian gland orifices Associated anomalies cleft-palate(fig.3),cardiac defects, varicose veins, ptosis, spinal extradural cysts, photophobia. All victims of this ailment are born with extra eyelashes, but the age that Lymphedema-Distichiasis Syndrome develops in these patients can vary, inflicting them by the age of 40. Men with this ailment typically develop Lymphedema earlier than women do.

**CASE REPORT:** A 32 year old male patient presented with swelling of both legs since 15 years and difficulty in walking since 10 years. History of nasal speech since childhood and regurgitation of fluids from nose. He underwent ASD closure surgery two years back.

On examination patient had thick double eye lashes, Cleft palate, and Non- pitting edema over bilateral lower limbs. On left side swelling extended from below the knee to feet in the posterior and lateral aspects measuring about 25\*20 cms. He had varicose veins noted over both lower limbs.No lymphadenopathy, Vitals- WNL.

Clinical diagnosis of Lymphedema-distichiasis syndrome was made.

# CASE REPORT

---

## INVESTIGATIONS:

- Peripheral smear negative for microfilaria,
- Echocardiography was WNL,
- MRI of Left leg showed multiple, dilated hyperplastic lymphatic channels.
- Gene Analysis report awaited.

Patient underwent debulking surgery-HOMANS PROCEDURE on left lower limb. Post-op patient was put on antibiotics and NSAIDs and was discharged on 15<sup>th</sup> post-op day.

**DISCUSSION:** LDS is a primary lymphatic disorder. Mutations in FOXC2 (Forkhead Box C2) impact the function of its associated protein, also named FOXC2. [2]

75% of all individuals with LDS are symptomatic and usually affected by lymphedema (LE) by forties [2, 3] and distichiasis (double row of eyelashes), for which the condition is named. LE related to LDS manifests in the lower limbs with characteristically asymmetrical swelling.

Distichiasis occurred in 94% of patients, 74% of whom had complications, including corneal irritation, photophobia, conjunctivitis, and styes. Ptosis in 31%, congenital heart disease in 6.8%, and cleft palate in 4%. Varicose veins, present in 49%, were notable for early onset and increased prevalence compared to the general population [2]. Late onset hereditary lymphedema can be divided into 4 types. They are:

- 1) Lymphedema praecox of Meige type, clinically evident at puberty and not associated with extra cutaneous features.
- 2) Clinically indistinguishable from Meige type and may involve hypoplasia of lymphatics due to recurrent lymphangitis with /without recurrent cellulitis.
- 3) Associated with cerebral AV malformations and pulmonary hypertension.
- 4) LD syndrome which is very rare and presents during adolescence. This fourth type is associated with distichiasis. Other ophthalmologic findings may include photophobia, corneal irritation, and partial ectropion of lateral third of eyelashes. Associated abnormalities include congenital heart disease [4, 5] webbed neck, vertebral abnormalities and capillary haemangiomas [6]. The diagnosis of lymphedema-distichiasis syndrome is made clinically based on the presence of primary lymphedema and distichiasis. FOXC2 is the only gene in which mutations are known to cause lymphedema-distichiasis syndrome.

Medical evaluations for the Lymphedema-Distichiasis Syndrome may include slit-lamp examinations by an Ophthalmologist, physical examinations to determine manifestation presence and cellulitis evidence, Isotope Lymphoscintigraphy [10] for confirming lymphatic abnormalities, and heart examinations if Arrhythmia or heart murmurs are detected. An echocardiography may also be required. [7].

Management of the Lymphedema-Distichiasis Syndrome includes a treatment phase of daily multi-layered, minimally elastic bandages, possibly combined with manual lymph drainage, to reduce the size of the lymphedema. This treatment is followed by a maintenance phase consisting of wearing compression garments to reduce lymph fluid buildup. Skin care is necessary to prevent infections that may develop with this condition. To prevent secondary cellulitis treat athlete's foot and other infections promptly; treat early cellulitis with antibiotics. Diuretics are not effective in the treatment of lymphedema. Lubrication, plucking, cryotherapy, electrolysis, or lid splitting for

# CASE REPORT

---

treatment of distichiasis; fitted stockings and bandages to improve swelling and discomfort associated with edema<sup>[9]</sup>

Genetic counselling is done in these cases. Lymphedema-distichiasis syndrome is inherited in an autosomal dominant manner. Approximately 75% of affected individuals have an affected parent; about 25% have de novo mutations. Each child of an individual with lymphedema-distichiasis syndrome has a 50% chance of inheriting the mutation. Disease severity cannot be predicted and is variable even within the same family. Prenatal testing for pregnancies at increased risk is possible if the disease-causing mutation has been identified in an affected family member; however, it is rarely requested. Fetal echocardiography is recommended because of the increased risk for congenital heart disease.

**CONCLUSION:** LDS is one of the rare syndromes reported. Prompt clinical diagnosis and early identification will help in accurate treatment of this syndrome.

## REFERENCES:

1. Sutkowska E, Gil J, Stembalska A, Hill-Bator A, Szuba A. Novel mutation in the FOXC2 gene in three generations of a family with lymphoedema-distichiasis syndrome. *Epub2012*, 2012 Apr 25;498(1):96-9. Doi: 10.1016/j.gene.2012.01.098.
2. Brice G, Mansour S, Bell R, Collin, J R.O, Child AH, Brady AF, et al. Analysis of the phenotypic abnormalities in lymphoedema-distichiasis syndrome in 74 patients with FOXC2 mutations or linkage to 16q24. *J. Med. Genet* 2002; 39: 478-483.
3. Erickson RP, Dagenais SL, Caulder MS, Downs CA, Herman Get al. Clinical heterogeneity in lymphoedema-distichiasis with FOXC2 truncating mutations. *J Med Genet.* 2001; 38:761-6.
4. Corbett, C. R. R.; Dale, R. F.; Coltart, D. J.; Kinmonth, J. B. :Congenital heart disease in patients with primary lymphoedemas. : *PubMed*; 1982: 85-90.
5. Chen E, Larabell SK, Daniels JM, Goldstein S. Distichiasis-lymphedema syndrome: tetralogy of Fallot, chylothorax, and neonatal death. *Am J Med Genet.* 1996; 66:273-5.
6. Sandra Marchese J, Kincannon JM, Thomas D, Horn MD. Lymphedema-Distichiasis Syndrome: Report of a Case and Review. *Arch Dermatol.*1999; 135(3):347-348.
7. Mansour S, Brice GW, Jeffery S, Mortimer P. Lymphedema-Distichiasis Syndrome. *Gene Reviews™* [Internet]. Seattle (WA): University of Washington, Seattle; 1993-2013. 2005 Mar 29 [updated 2012 May 24].
8. Finegold DN, Kimak MA, Lawrence EC, Levinson KL, Cherniske EM, Pober BR, Dunlap JW, Ferrell RE. Truncating mutations in FOXC2 cause multiple lymphedema syndromes. *Hum Mol Genet.* 2001; 10:1185-9.
9. O'Donnell BA, Collin JR. Distichiasis: management with cryotherapy to the posterior lamella. *Br J Ophthalmol.* 1993; 77:289-92.
10. Rosbotham JL, Brice GW, Child AH, Nunan TO, Mortimer PS, Burnand KG. Distichiasis-lymphoedema: clinical features, venous function and lymphoscintigraphy. *Br J Dermatol.* 2000; 142:148-52.

## CASE REPORT

---

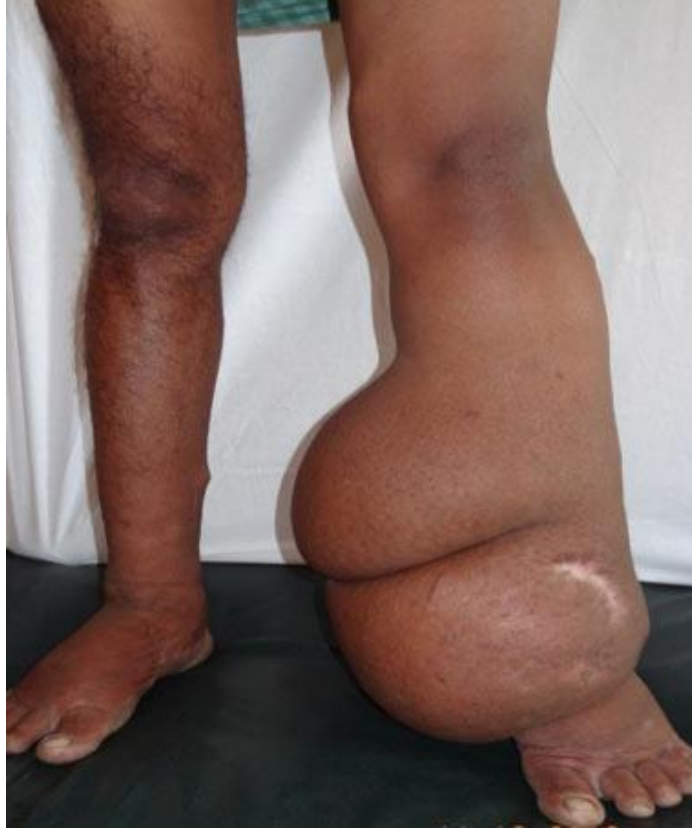

Image 1 showing Lymphedema of left lower limb

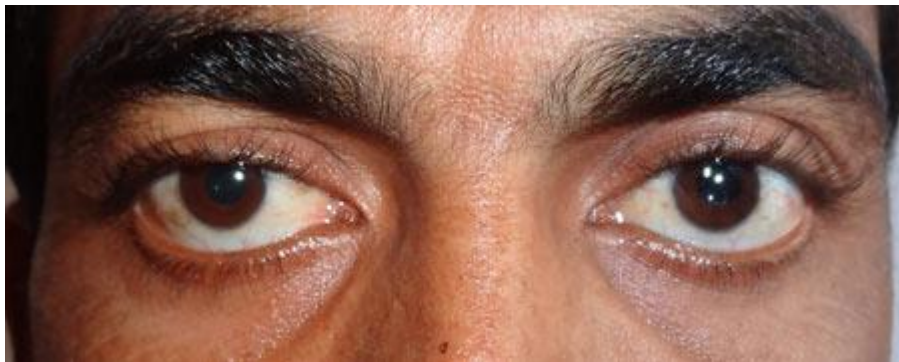

Image 2 showing double row of eyelashes

# CASE REPORT

---

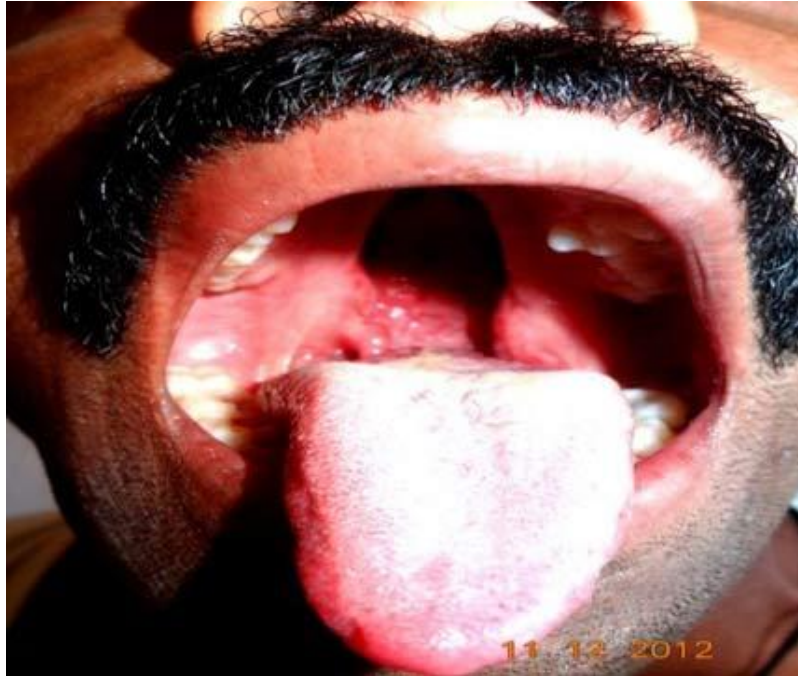


Image 3 showing cleft palate

## **AUTHORS:**

1. Dayanand S. Biradar
2. Hemanthkumar M.
3. Supreet Ballur

## **PARTICULARS OF CONTRIBUTORS:**

1. Senior Resident, Department of General Surgery, BLDE University's Shri B.M. Patil Medical College and Research Center, Bijapur.
2. Associate Professor, Department of General Surgery, BLDE University's Shri B.M. Patil Medical College and Research Center, Bijapur.
3. Junior Resident, Department of General Surgery, BLDE University's Shri B.M. Patil Medical College and Research Center, Bijapur.

## **NAME ADDRESS EMAIL ID OF THE CORRESPONDING AUTHOR:**

Dr. Dayanand S Biradar,  
Senior Resident,  
Department of General Surgery,  
Shri B.M. Patil Medical College and Research  
Center, Bijapur, 586103.  
Email- drdayanandbiradar@gmail.com

Date of Submission: 14/08/2013.  
Date of Peer Review: 16/08/2013.  
Date of Acceptance: 19/08/2013.  
Date of Publishing: 21/08/2013